



A Combined Hypnosis-echography Therapy in Irritable Bowel Syndrome: A Pilot Study

**Danilo Sirigu¹, Nino Sole², Monica Musio³, Paolo Usai-Satta^{4*}
and Francesco Oppia⁴**

¹Radiology Unit, Brotzu Hospital, Cagliari, Italy.

²Private Psychologist, Cagliari, Italy.

³Department of Mathematic, University of Cagliari, Italy.

⁴Gastroenterology Unit, Brotzu Hospital, Cagliari, Italy.

Authors' contributions

This work was carried out in collaboration between all authors. Author DS designed the study, performed the Echo-hypnosis protocol, and wrote the first draft of the manuscript. Author NS performed the Echo-hypnosis protocol. Author MM performed the statistical analysis. Authors PUS and FO managed the literature searches and wrote the first draft of manuscript. All authors read and approved the final manuscript.

Article Information

DOI: 10.9734/JAMMR/2018/40669

Editor(s):

(1) Syed Faisal Zaidi, Department of Basic Medical Sciences, College of Medicine, King Saud Bin Abdulaziz University-HS, National Guard Health Affairs, King Abdulaziz Medical City, Kingdom of Saudi Arabia.

Reviewers:

(1) Tolga Dinç, Ankara Numune Training Hospital, Turkey.

(2) Yavuz Savas Koca, Suleyman Demirel University, Kazakhstan.

Complete Peer review History: <http://www.sciencedomain.org/review-history/23919>

Received 9th January 2018

Accepted 27th March 2018

Published 31st March 2018

Original Research Article

ABSTRACT

Aims: Irritable bowel syndrome (IBS) is a disorder that can severely impair quality of life. While several treatments are available, their efficacy has not been completely proved. Aim of our study was to evaluate the therapeutic efficacy of a new technique which combines traditional clinical hypnosis with echography.

Methodology: of 31 IBS patients (28 F), 10 underwent combined clinical hypnosis-echography treatment, which was carried out during one 2-hour session per week for 4 months. This protocol combines hypnotherapy with echographic visualization of the abdominal organs. Treatment efficacy was evaluated utilising a symptom questionnaire and was then compared with that achieved in two control groups: one consisting of 11 patients treated with hypnotherapy alone, the other made up of 10 patients treated with conventional drug therapy.

Results: The results revealed that treatment with hypnosis-echography was more efficacious than

*Corresponding author: E-mail: paolousai@aob.it;

the other two therapies, the difference being more marked in comparison with drug therapy. Abdominal pain had better results but also bowel habits and quality of life improved after this combined treatment.

Conclusions: the combination of hypnosis and echography can be effective in controlling IBS symptoms and in improving the quality of life of the patients treated. The best results were obtained concerning pain. This experimental protocol enables patients to increase their awareness of their own bodies and to focus the psychic and biochemical resources elicited by hypnosis on the target organs identified by echography. This experience might further broaden the field of application of echography.

Keywords: Gut-directed hypnosis; irritable bowel syndrome; abdominal pain; bowel disorders.

1. INTRODUCTION

Irritable bowel syndrome (IBS), which is commonly defined according to the criteria of Rome IV [1], is characterized by the presence of recurrent abdominal pain or discomfort for at least three days per month in the last three months, with the onset of symptoms dating back at least six months, associated to at least two of the following features: pain alleviated by defecation, and/or onset associated to a change in frequency of defecation, and/or change in the shape of the feces.

This pathology affects 10 – 20% of the population, has a higher prevalence among females (4:1) and displays no ethnic difference. Onset often occurs in concomitance with stressful events or following acute gastroenteritis. It is regarded as a biopsychosocial disease, in that it considerably impairs the subject's quality of life in about 40% of cases [2]. However, no increased risk of neoplasia or death has ever been documented.

Four clinical subtypes have been described; these are classified according to the characteristics of the patient's bowel movements, which may be diarrhea-predominant (IBS-D), constipation-predominant (IBS-C), mixed (IBS-M) or undetermined (IBS-U) type [1,3].

The diagnosis is based on the symptoms (Rome IV criteria) and the absence of organic pathologies, which are excluded using laboratory and instrumental investigations (e.g. colonoscopy), in the presence of alarm signals (weight loss, blood in the feces, fever, anemia, abdominal masses) [3].

Pharmacological treatment is chiefly symptomatic [4,5]; in prevalently diarrheal forms, drugs such as Loperamide, antibiotics, and probiotics may be used, while in constipation

forms, fibers or Macrogol and, sometimes, partial serotonin agonists (Procalupride) and pro-secretory agents (Linaclotide) are used [6]. Antispasmodics are administered to treat abdominal pain. While tricyclic antidepressants and selective serotonin reuptake inhibitors (SSRI) can alleviate pain, they are particularly indicated for the treatment of the psychological disorders and anxiety that often accompany IBS [7]. Several papers have reported the efficacy of gut-directed hypnotherapy in treating IBS. This technique has proved to elicit great patient satisfaction; one notable advantage is that, rather than alleviating a single symptom, it improves many aspects of the condition, including quality of life [8-16]. Hypnosis is a modified state of consciousness – i.e. a standard psychosomatic phenomenon which involves the subject's psychological and physical dimensions – in which some functions of the organism (neurovegetative, neuroendocrine, immune systems) can be modified. In the last 20 years, echography has been used with great diagnostic reliability to evaluate the gastrointestinal tract [17-19], although only in the last decade has it been accepted as a first-line tool in the diagnosis and monitoring of inflammatory bowel diseases. Besides this technique can usefully differentiate between organic and functional bowel conditions. The aim of the present study was to test a new diagnostic-therapeutic approach to the treatment of IBS in which echography interacts with clinical hypnosis in order to achieve a clinical benefit in these patients and finally reach a better quality of life.

2. MATERIALS AND METHODS

2.1 Study Design

We have conducted a non-randomized clinical trial with historical controls. The study was performed in Cagliari, Italy, at Brotzu Hospital, where 31 patients (28 F, 12 IBS-D, 11 IBS-C, 8

IBS-M) with IBS were recruited in a highly specialized unit for functional GI disorders, between March 2013 and January 2014. More specifically we have data from 10 subjects (9 F, aged between 17 and 57 yrs) who performed a Eco-Hypnosis therapy (EH). This procedure was performed 2 h per week for 4 months. These patients have been compared with two control groups. The first group (11, 2 men and 9 women aged between 21 and 41 yrs) was treated with Hypnosis (H) alone (2 h per week for 4 months). The second group (10 women, aged between 22 and 79 yrs) was treated with a pharmacological approach (P), including antispasmodic agents, antidiarrhoeal or anti-constipation drugs, where necessary. None patient was treated with antidepressant agents. All participants included in the study met the Rome IV criteria for IBS [1].

2.2 Echo-hypnosis Protocol

We used an ESAOTE My Lab Class C echograph. The examination started with a standard abdominal probe (3-5 MHz) that gave an overall view on the distribution, location and relationship to neighbouring structures of the small intestine and colon loops. Subsequently, we have focused the examination on high-frequency probes (7-12 MHz) necessary for a detailed examination of the previously identified segments, to evaluate bowel wall with higher resolution.

The echographic image was then projected onto a wall in front of the patient at a distance of about 3 meters.

While lying on a bed, the patient listened to the voices of the therapists (physician and psychotherapist) through headphones, over background music.

This echo-hypno protocol involves one 2-hour treatment session per week for four months.

Each session consisted of seven phases.

2.3 Phase 1: Relaxation

The patient begins relaxation by putting on the headphones and listening to a particular music a frequency of 432 Hz.

Over this background music, the operator prompts the patient to relax the various groups of muscles in sequence.

2.4 Phase 2: Echographic Visualization

The state of relaxation induced facilitates the patient's concentration on the echographic visualization of his/her internal organs. Having acquired a representation of these organs, the patient then maintains a "mnemonic trace" of them.

While the echographer performs the examination, the echographic images are projected onto the wall by means of a projector connected to the audio-video output of the echograph; this also to listen to the blood flow in vessels sampled.

In this way, the patient views the echographic images as the examination is carried out, thereby becoming aware of and familiar with his/her own internal organs and making a sort of interior journey. This creates a particular contact between the patient and his/her intestine, which was previously seen as a foreign body engaged in a conflictual relationship, as it was deemed to be responsible for the patient's suffering.

2.5 Phase 3: Deepening Double Induction

1. Two hypnotists interact to determine a cognitive overload
2. Hypnotist 1: linear and sequential logical induction
3. Hypnotist 2: classic induction using metaphorical and sensorial linguistic schemes.
4. The patient progressively moves from a state in which the critical faculty is suspended to one in which he/she tends to comply with the suggestions made, which are accepted, internalized and experienced as reality.

2.6 Phase 4: Metaphor

The person and the symptoms are restructured through metaphorical suggestions of well-being, calmness and awareness, which can reverberate on the image and therefore on the organs individuated echographically.

The aim of this phase is to stimulate a creative process that can evoke new associations within the patient.

2.7 Phase 5: Plastic Monodeism

In this phase, the concrete manifestation of the power of the mental representation induced by

clinical hypnosis is experienced; this representation is manifested as a biological fact through Plastic Monoideism, which reflects the internal experience at the bodily level (creative monoideism) [20].

The idea of well-being utilizes the energy inherent in itself to create the feeling of well-being.

The idea of levitation and of drawing an arm upwards causes the arm to feel lighter and to be raised. Levitation, catalepsy and modification of the respiration rate and muscle tone very clear examples of plastic monoideism.

The achievement of plastic monoideism also provides the certainty that the patient is really under hypnosis.

2.8 Phase 6: Therapeutic Restructuring

On the basis of what has been said, therapeutic restructuring takes place simultaneously on two levels, which reciprocally integrate with each other:

- 1 Somatic level
- 2 Psychic level

AT THE SOMATIC LEVEL, therapeutic restructuring occurs through a theoretic biochemical modifications induced by the creation of hypnosis-induced emotional states in accordance with the scientific model of psychoneuroendocrinoimmunology [21,22].

AT THE PSYCHIC LEVEL, it takes place through a process of learning that requires the patient to be willing to change harmful, repetitive, mental patterns. In this sense, hypnotherapy constitutes an amplifier for experience and a process of learning in which the patient is directed towards greater autonomy and self-efficiency; this is achieved by raising the patient's self-esteem and self-confidence and by helping him/her to reduce and manage anxiety and apprehension and to improve his/her ability to integrate the new associations generated during echo-hypnotherapy and to link them to real-life experience.

2.9 Final Phase: Re-orientation

Re-orientation marks the conclusion of "setting". It amounts to facilitating the patient's progress in re-adaptation to the environment. At the end of setting, the patient is interviewed in order to analyze the phases and the emotional experience of setting together.

2.10 Symptom Questionnaire

The patients in the present study were asked to fill in a symptom questionnaire at the beginning and end of treatment. The questionnaire was modified from a standard severity score [23] and tailored to our study: a simplified score from 0 to 3 was calculated for each items.

We compared the pre- and post-treatment values of four variables: pain, abdomen distension, bowel habits and quality of life. Table 1 reports the detail of the variables analyzed.

Table 1. Symptom score questionnaire

Question	Variable	Categories
Do you often suffer from abdominal pain ?	Pain	0= no pain 1= non-severe pain 2= severe pain
Do you often suffer from abdominal swelling ?	Abdomen distension	0= no distension 1= not much distention 2= marked distention
How satisfied are you with your bowel habits ?	Bowel habits	0= very satisfied 1= quite satisfied 2= dissatisfied
How much does your intestinal problem interfere with your general quality of life ?	Quality of life	0 = not at all 1 = not very much 2= quite/very much

2.11 Statistical Analysis

Comparison between individual groups of patients was performed pre- and post-treatment by means of Fisher's exact test of independence for r X c tables. A proportional odds model [24] was applied to compare type of therapy and symptom scores. All analyses were carried out by means of the STATA statistical package.

2.12. Ethics

The study was approved by the Brotzu Hospital Ethical Committee for Research in Health in Cagliari, Italy. An informed consent was obtained for all the participants.

3. RESULTS

Overall changes in the variables analyzed were assessed by comparing pre- and post-treatment values in the three groups of patients. The results are shown in the bar-plots reported in Figs. 1-4. Prior to treatment, there were no significant differences among the three groups in the variables considered, while post-treatment there were significant differences in the following variables: "Pain" (p <0.005), "abdominal distension" (p <0.01), "Bowel Habits" (p <0.005), "Quality of life" (p <0.02). The different predominant symptom of IBS patients (diarrhea, constipation or mixed) did not influence the results. To highlight the difference between patients treated with EH and patients of control groups, we focused on the variable "Pain" as the main factor characterizing the syndrome. As can be seen from Fig. 1, all patients in the study started from the same initial situation (severe pain). For this reason, we defined a new variable (denoted by Y) that takes into account the difference between the perception of pain (scores) at the beginning and end of the treatments. This ordinal variable takes the value "0" if the patient shows no improvement at the end of the treatment, "1" if the condition persists but has obviously improved (the patient downgrades the pain from "severe" to "non-severe") and "2" if the patient no longer has pain at the end of the study. The variable Y is independent of the variables "Sex" (p = 0.76) and

"Age", the latter being dichotomized into two categories: age 15-35 years; > 35 (p = 0.23). To study the relationship between Y and the variable "type of therapy," we applied a proportional odds model. The odds ratio is assumed to be constant for all categories (we verified the validity of these assumptions in our study by means of a likelihood ratio test). Results of the analysis, in terms of odds ratio, are displayed in Table 2. The odds on "some improvement" (partial or total) versus "no improvement", when all other variables in the model are held constant, are 6 times greater for those treated with both hypnosis and echography than for those receiving hypnosis alone. Likewise the odds on "full recovery" versus "less than full recovery", when all other variables in the model are held constant, are 6 times greater for those treated with both hypnosis and echography than for those receiving hypnosis alone. On comparing EH patients with those treated with P, the odds on "some improvement" versus "no improvement" ("full recovery" versus "less than full recovery") when all other variables in the model are held constant, are 56 times greater for those treated with both hypnosis and echography than for those receiving the pharmacological therapy. Despite the small sample sizes and, consequently, the very wide confidence intervals, the results revealed that treatment with hypnosis-echography was more efficacious than the other two therapies, the difference being more marked in comparison with pharmacological therapy (p < 0.001).

4. DISCUSSION

Irritable bowel syndrome is quite prevalent in the general population and represents the functional gastrointestinal disorder most frequently encountered in primary and secondary care. As known this disorder has a great impact on the quality of life. The therapeutic approach depends on the intensity of symptoms and the degree of psychosocial comorbidities. Initial treatment is directed towards education, reassurance and lifestyle modification. In a second phase, an appropriate pharmacotherapy can be proposed on the basis of individual or global intestinal symptoms and/or psychological disturbances.

Table 2. Odds ratios, extremes of confidence intervals and p-values of the test used to verify the significance for each therapy (EH: Echo-Hypnosis therapy; P: Pharmacological therapy)

Type of therapy	OR	2,50%	97,50%	p-value
EH	5,72	1,02	40,21	0,06
P	56,13	6,75	727,12	<0,001

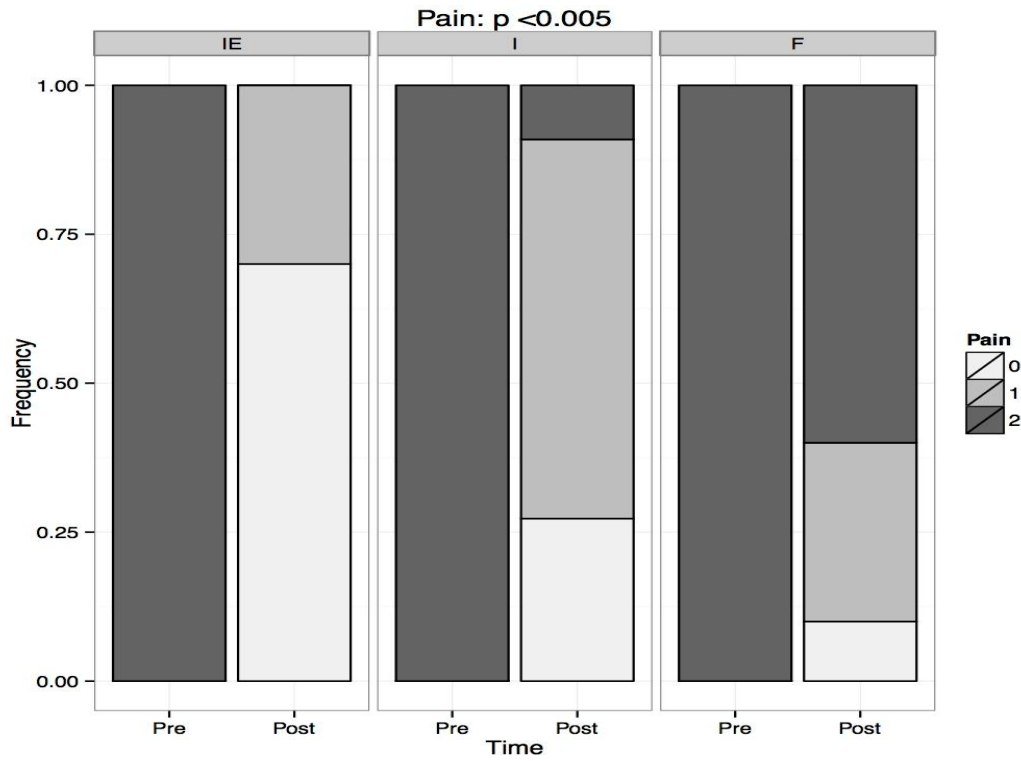


Fig. 1. Pre and post-treatment differences for pain (0-1-2: score)

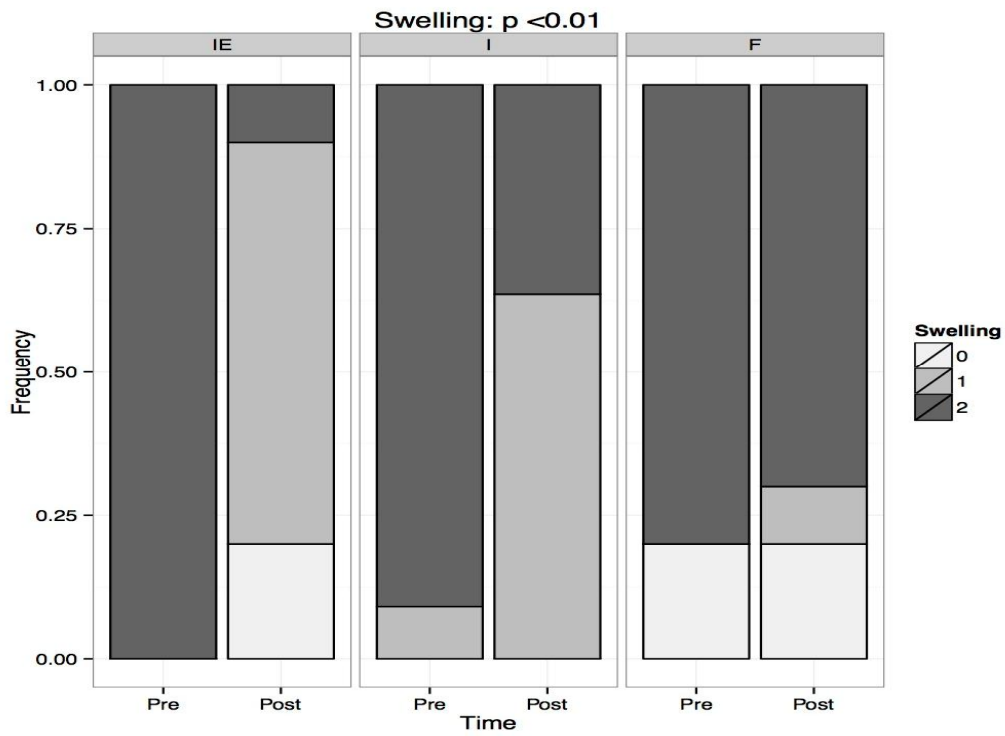


Fig. 2. Pre and post-treatment differences for abdomen distension (0-1-2: score)

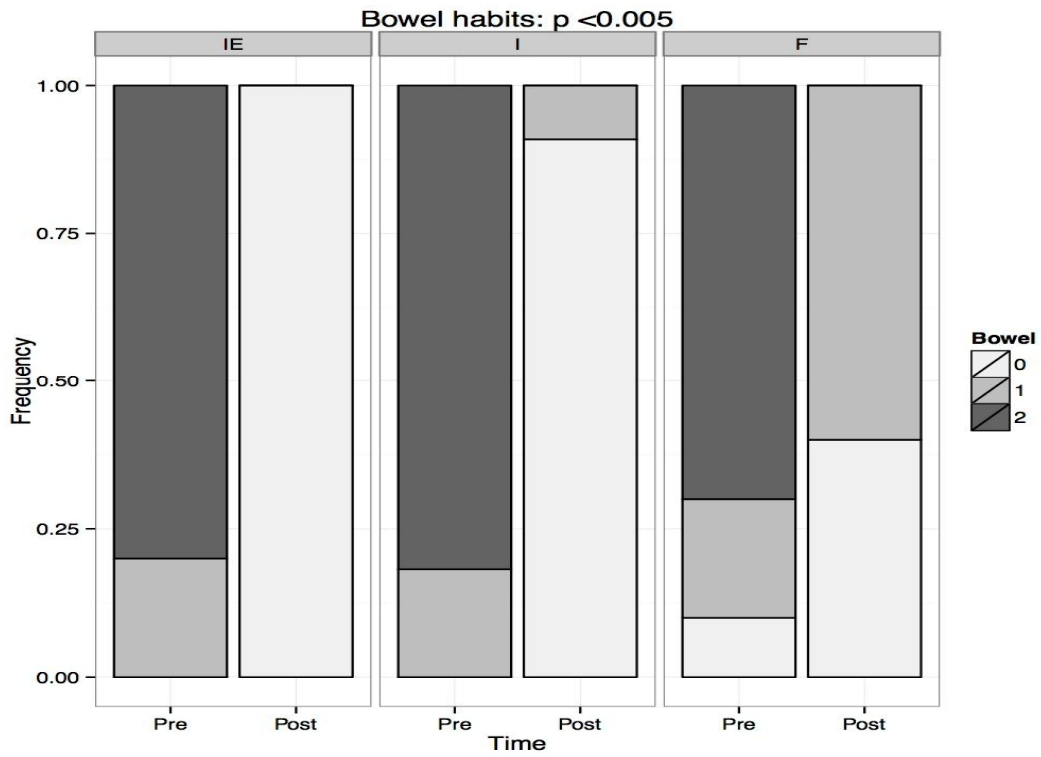


Fig. 3. Pre and post-treatment differences for bowel habits (0-1-2: score)

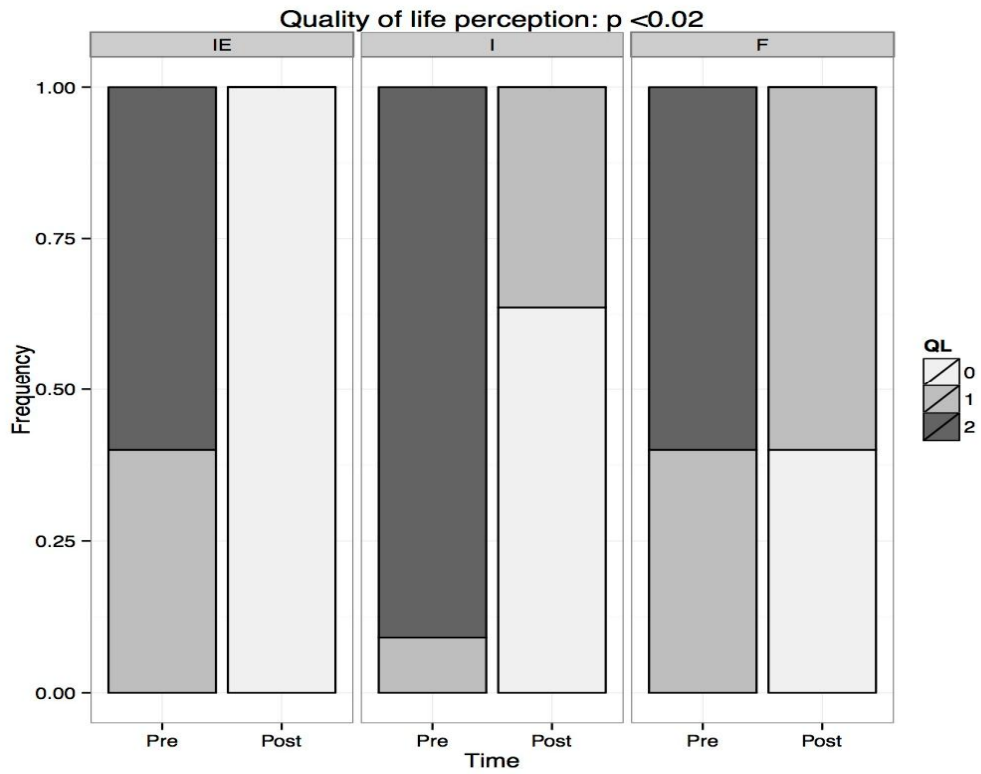


Fig. 4. Pre and post-treatment differences for Quality of life (0-1-2: score)

The efficacy of hypnotherapy in the treatment of IBS has been documented in numerous studies [8-15]. The mechanism through which hypnotherapy improves abdominal pain in IBS patients is however not well understood. Hypnotic reduction of somatic pain is thought to reduce the activation of certain areas of the brain, which appears to be exaggerated in IBS. It is also assumed that hypnotherapy normalizes visceral sensation and decreases colonic phasic contractions. On the other hand no sufficient data are available about the standardization of the gut-directed hypnotherapy and a detailed hypnotic protocol is rarely reported in the other published studies on IBS. On the contrary in our study a detailed sequence of the hypnotic technique was described. The hypnotic process is an interaction based on the reciprocal power shared by the therapist and patient, the purpose of which is to achieve a therapeutic result. Indeed, the hypnotic approach centers on the therapist's ability to enter into a relationship with the patient through a flexible attitude that meets the individual needs of the patient.

The originality of the present study lies in the fact that hypnotherapy was combined with echography and that this diagnostic tool was used to visualize the target organs, thereby providing the patient with greater knowledge, awareness and familiarity with his/her own body.

Moreover, when combined with clinical hypnosis, echography enables the patient to focus the psycho-biochemical resources elicited by hypnotherapy on the target organs visualized echographically. Thus, psychosomatic-visceral responses are evoked in a therapeutic "virtuous circle" between mind and body.

Indeed, in the creative act induced by hypnosis-echography, the relationship between imagination and image can be expressed as a therapeutic act; the imagination generates a potent dynamic on the image, evoking and reverberating upon it a psycho-neuro-immuno-endocrine-related emotional cascade [21,22].

Combining echography with hypnosis increases therapeutic potential in comparison with hypnotherapy alone in controlling and/or resolving the symptoms of irritable bowel syndrome. This therapeutic efficacy proved particularly evident with regard to pain, which is a characteristic and invalidating symptom of the

syndrome. According to previous experiences with hypnotherapy alone in IBS, overall symptoms and quality of life were however improved after treatment, but the combination of these techniques seems further strengthen these results.

On the other hand, the limitations of this study can be represented by the small number of patients and the short period of follow-up, but gut-directed hypnotherapy combined with echography could become a useful and safe therapeutic option for refractory IBS. Further large sample and high-quality RCTs are needed for confirming these results and evaluating the long-term efficacy of this technique.

5. CONCLUSIONS

Many different therapies have been suggested for IBS treatment, but their real benefits are very debatable. Several studies have reported the efficacy of gut-directed hypnotherapy in treating IBS. It can improve many aspects of this condition, including quality of life.

The hypnosis-echography protocol can allow the patient to become the principal architect of the therapeutic result, and the doctor to considerably broaden the field of application of echography from the sphere of diagnosis to that of therapy. This approach can be a new therapeutic opportunity in the management of IBS patients.

CONSENT

As per international standard or university standard, patient's written consent has been collected and preserved by the authors.

ETHICAL APPROVAL

As per international standard or university standard, written approval of Ethics committee has been collected and preserved by the authors.

COMPETING INTERESTS

Authors have declared that no competing interests exist.

REFERENCES

1. Mearin F, Lacy BE, Chang L, Chey WD, Lembo AJ, Simren M, et al. Bowel

- disorders. *Gastroenterology* 2016;150: 1393–1407.
2. Wilson A, Longstreth G, Knight K, Wong J, Wade S, Chiou C, et al. Quality of life in managed care patients with irritable bowel syndrome. *Manag Care Interface* 2004; 17:24–28.
 3. Bellini M, Gambaccini D, Stasi C, Urbano MT, Marchi S, Usai-Satta P. Irritable bowel syndrome: a disease still searching for pathogenesis, diagnosis and therapy. *World J Gastroenterol* 2014;20(27):8807-20.
 4. Lesbros-Pantoflickova D, Michetti P, Fried M, Beglinger C, Blum AL. Meta-analysis: The treatment of irritable bowel syndrome. *Aliment Pharmacol Ther.* 2004;20:1253-1269.
 5. Tack J, Fried M, Houghton LA, Spicak J, Fisher G. Systematic review: The efficacy of treatments for irritable bowel syndrome-a European perspective. *Aliment Pharmacol Ther.* 2006;24:183-205.
 6. Blackshaw LA, Brierley SM.. Emerging receptor target in the pharmacotherapy of irritable bowel syndrome with constipation. *Exp Rev Gastroenterol Hepatol.* 2013;7 (Suppl 1):15-9.
 7. Ford AC, Talley NJ, Schoenfeld PS, Quigley EM, Moayyedi P. Efficacy of antidepressants and psychological therapies in irritable bowel syndrome: systematic review and meta-analysis. *Gut* 2009;58:367-378.
 8. Whorwell PJ, Prior A, Faragher EB. Controlled trial of hypnotherapy in the treatment of severe refractory irritable-bowel syndrome. *Lancet* 1984;2:1232-1234.
 9. Whorwell PJ, Prior A, Colgan SM. Hypnotherapy in severe irritable bowel syndrome: further experience. *Gut* 1987; 28:423-425.
 10. Miller V, Carruthers HR, Morris J, Hasan SS, Archbold S, Whorwell PJ. Hypnotherapy for irritable bowel syndrome: An audit of one thousand adult patients. *Aliment Pharmacol Ther* 2015;41(9):844-55.
 11. Palsos OS, Turner MJ, Johnson DA, Burnett CK, Whitehead WE. Hypnosis treatment for severe irritable bowel syndrome: investigation of mechanism and effects on symptoms. *Dig Dis Sci.* 2002; 47:2605-2614.
 12. Lindfors P, Ljótsson B, Björnsson E, Abrahamsson H, Simrén M. Patient satisfaction after gut-directed hypnotherapy in irritable bowel syndrome. *Neurogastroenterol Motil.* 2013;25(2):169-e86.
 13. Gonsalkorale WM, Houghton LA, Whorwell PJ. Hypnotherapy in irritable bowel syndrome: A large-scale audit of a clinical service with examination of factors influencing responsiveness. *Am J Gastroenterol.* 2002;97:954–61.
 14. Lindfors P, Unge P, Arvidsson P, Nyhlin H, Björnsson E, Abrahamsson H, et al. Effects of gut-directed hypnotherapy on IBS in different clinical settings-results from two randomized, controlled trials. *Am J Gastroenterol.* 2012;107(2):276-85. DOI: 10.1038/ajg.2011.340
 15. Lindfors P, Unge P, Nyhlin H, Ljótsson B, Björnsson ES, Abrahamsson H, et al. Long-term effects of hypnotherapy in patients with refractory irritable bowel syndrome. *Scand J Gastroenterol.* 2012; 47(4):414-20.
 16. Peters SL, Yao CK, Philpott H, Yelland GW, Muir JG, Gibson PR. Randomised clinical trial: the efficacy of gut-directed hypnotherapy is similar to that of the low FODMAP diet for the treatment of irritable bowel syndrome. *Aliment Pharmacol Ther.* 2016;44(5):447-59.
 17. Pallotta N, Baccini F, Corazziari E. Contrast ultrasonography of the normal small bowel. *Ultrasound Med Biol.* 1999;25:1335-40.
 18. Nylund K, Ødegaard S, Hausken T, Folvik G, Lied GA, Viola I, et al. Sonography of the small intestine. *World J Gastroenterol.* 2009;15:1319-30.
 19. Carnevale Maffè G, Brunetti L, Formagnana B, Corazza GR. Ultrasonographic findings in Crohn's disease. *J Ultrasound.* 2015;18(1):37-49.
 20. Kaffman M. Monoideism in psychiatry: theoretical and clinical implications. *Am J Psychother.* 1981;35(2):235-43. PMID: 7258420.
 21. Rossi EL. *The Psychobiology of mind-body healing.* W. W. Norton & Co, Inc, New York; 1986.
 22. Akmaev IG, Grinevich VV. From neuro endocrinology to neuro immune endocrinology. *Bulletin of Experimental Biology and Medicine.* 2001;131(1):15-23.

23. Francis CY, Morris J, Whorwell PJ. The irritable bowel severity scoring system: A simple method of monitoring irritable bowel syndrome and its progress. *Aliment Pharmacol Ther.* 1997;11(2):395-402.
24. McCullagh P. Regression models for ordinal data. *Journal of the Royal Statistical Society.* 1980(Series B);42:109–142.

© 2018 Sirigu et al.; This is an Open Access article distributed under the terms of the Creative Commons Attribution License (<http://creativecommons.org/licenses/by/4.0>), which permits unrestricted use, distribution, and reproduction in any medium, provided the original work is properly cited.

Peer-review history:
The peer review history for this paper can be accessed here:
<http://www.sciencedomain.org/review-history/23919>